



PATIENT

Negan Kodi's Club

SPECIES

Canine

BREED

Rottweiler

SEX

Male Intact

AGE

9.3 months

WEIGHT

72lbs

INTERPRETED BY

Maggie Machen Lamy,
DVM, DACVIM
(Cardiology)

IMAGING PERFORMED BY

Kristen Carpenter,
DVM

HOSPITAL NAME

Penridge Animal
Hospital

REFERRING VET

Dr. Kristen Carpenter

INVOICE

47583

DATE

4/15/26

PRESENTING CLINICAL SIGNS

History: Grade 3/6 heart murmur. Asymptomatic. BP: 233, 210mmHg (excited). Sedated with Torb.

ECHOCARDIOGRAM FINDINGS

2D, m-mode, color flow and doppler imaging is available. Normal mitral valve leaflets are mildly abnormal with prolapse into the LVOT suspected. No obvious mitral regurgitation. Normal left atrial dimension. Normal LV diameter with adequate myocardial function. The LV wall thickness appears normal. The tricuspid valve appears normal with no TR. Moderate right atrial dilation. Significant right ventricular hypertrophy and remodeling indicative of pressure overload. Right ventricular dilation. Pulmonic outflow velocities are elevated. The pulmonic valve appears severely thickened, tethered and stenotic. There is significant post-stenotic dilation of the main pulmonary artery and branches. Moderate pulmonic insufficiency. The aortic valve appears to have normal morphology and mobility. Mildly elevated LVOT velocity. No AI. The LVOT is poorly visualized. No obvious cardiac shunts are present. No pericardial or pleural effusion noted.

CARDIAC CHART

CANINE CARDIAC PARAMETERS	MR VMAX (m/s)	TR VMAX (m/s)	LA/AO (Boon method)	LA/AO (Heart Base; Swe)	FS (%)	EF (%)	EPSS (cm)
NORMAL PARAMETER	4.5-5.5	<2.7	1.3	<1.6	28-40	40-100	<0.6
PATIENT	NA	NA	1.2	1.2	46	90	0.3
CANINE CARDIAC PARAMETERS	HR (BPM)	AV VMAX (m/s)	PV MAX (m/s)	BODY WEIGHT (kg)	LA 2D short axis Base view (cm)	LVIDd Avg; 2D and m-mode short axis (cm)	LVIDs Avg; 2D and m-mode short axis (cm)
NORMAL PARAMETER	50-100	0.7-1.7	0.7-1.6	BELOW	BELOW	BELOW	BELOW
PATIENT	NM	2.3	6.5	32.7	2.7	3.0	1.6
*Normal chamber parameters expressed as a mean value (SD)				3	1.27 (5.3)	2.46 (2.46)	1.36 (5.5)
BODY WEIGHT DEPENDENT PARAMETERS				5	1.40 (4.5)	2.74 (5.2)	1.60 (4.7)
<i>*Note: All measurements based upon multi-modal images and methods. An average value is reported.</i>				10	1.50 (3.8)	3.27 (3.5)	2.06 (3.1)
				15	1.83 (2.0)	3.71 (2.4)	2.43 (2.1)
				20	2.02 (1.9)	4.14 (2.2)	2.80 (2.0)
				25	2.18 (2.4)	4.48 (2.9)	3.10 (2.5)
				30	2.33 (3.3)	4.83 (3.9)	3.39 (3.4)
				35	2.48 (4.3)	5.17 (5.0)	3.69 (4.5)
				40	2.62 (5.2)	5.48 (6.1)	3.96 (5.4)
				50	2.88 (7.1)	6.07 (8.3)	4.46 (7.4)

INTERPRETATION OF THE FINDINGS & FURTHER RECOMMENDATIONS

The cause of the murmur is severe valvular pulmonic stenosis. The degree of obstruction is severe based upon the velocity/pressure gradient across the pulmonic valve and the secondary hypertrophy and remodeling of the right ventricle. There is significant RA dilation suggesting risk for CHF is elevated and may limit lifespan. The mitral valve is also mildly abnormal consistent with dysplasia. The anterior leaflet can be seen prolapsing in the aortic outflow tract, causing a mild obstruction. This is comparatively insignificant. The LVOT is poorly visualized and a



PATIENT

Negan Kodi's Club

SPECIES

Canine

BREED

Rottweiler

SEX

Male Intact

AGE

9.3 months

WEIGHT

72lbs

INTERPRETED BY

Maggie Machen Lamy,
DVM, DACVIM
(Cardiology)

IMAGING PERFORMED BY

Kristen Carpenter,
DVM

HOSPITAL NAME

Penridge Animal
Hospital

REFERRING VET

Dr. Kristen Carpenter

INVOICE

47583

DATE

4/15/26

concurrent SAS or similar is not ruled out. No additional issues are seen. however, small shunts or defects can be difficult to identify without a sedated bubble study in patients this young.

Referral for balloon valvuloplasty should be considered in this patient as the gold standard therapeutic option for this condition, which may improve long term outcome and delay onset of clinical signs (such as exertional syncope or right-sided congestive heart failure). If surgery is not elected, this patient's condition may limit lifespan, with many severe PS cases developing CHF by mid-life. Regardless, medical management with atenolol is recommended as below to decrease heart rate and lessen the obstruction as below. Monitor for development of associated clinical signs (collapse, abdominal distention, cough, labored breathing). **Mild exercise restriction is advised lifelong.**

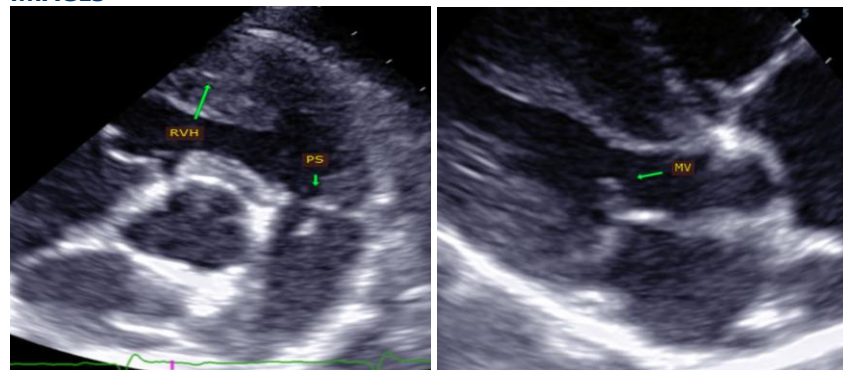
Breeding this animal is not advised due to the genetic link of this disease.

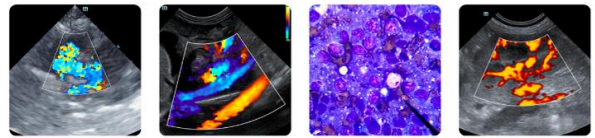
Anesthetic risk is mild to moderate at this time. **Avoid heart rate stimulating drugs such as atropine or glycopyrrolate unless absolutely necessary.** Avoid vasodilators such as acepromazine. Mild IV fluid restriction is advised. Cardiac protective drug choices (opioid/benzodiazepine premedication, propofol or alfaxalone induction, isoflurane gas) are recommended. Pre-oxygenate for 5-10 minutes prior to induction and recover in O2 if possible. Monitor for arrhythmias, hypotension, and hypoxia both intra and post-operatively and intervene as necessary.

Plan: Institute atenolol to effect: 25mg tabs, ¼ tab PO BID to start (up-titrate to desired effect). Goal is to suppress heart rate <120-140bpm even with stress/activity. Baseline chest radiographs and ECG are recommended. Referral for evaluation and balloon valvuloplasty if desired.

If surgery is declined, recommend recheck echocardiogram in 6-12 months to assess for progression, response to medication.

IMAGES





PATIENT

Negan Kodi's Club

SPECIES

Canine

BREED

Rottweiler

SEX

Male Intact

AGE

9.3 months

WEIGHT

72lbs

INTERPRETED BY

Maggie Machen Lamy,
DVM, DACVIM
(Cardiology)

IMAGING PERFORMED BY

Kristen Carpenter,
DVM

HOSPITAL NAME

Penridge Animal
Hospital

REFERRING VET

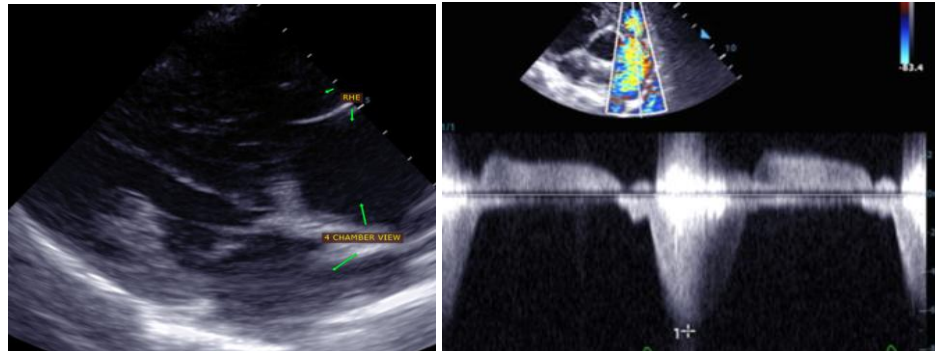
Dr. Kristen Carpenter

INVOICE

47583

DATE

4/15/26



The information and recommendations provided are based on the images presented by the referring veterinarian. No evaluation can be communicated regarding pathology that was not visible in the image/video clips provided.

Thank you for this referral. This report was generated using transcription software, and minor dictation errors may be present. If the clinical or image interpretation does not parallel your findings or if I can be of any further assistance, please contact me.

Maggie Machen Lamy, DVM
Diplomate of the American College of Veterinary Internal Medicine (Cardiology)
info@sonopath.com